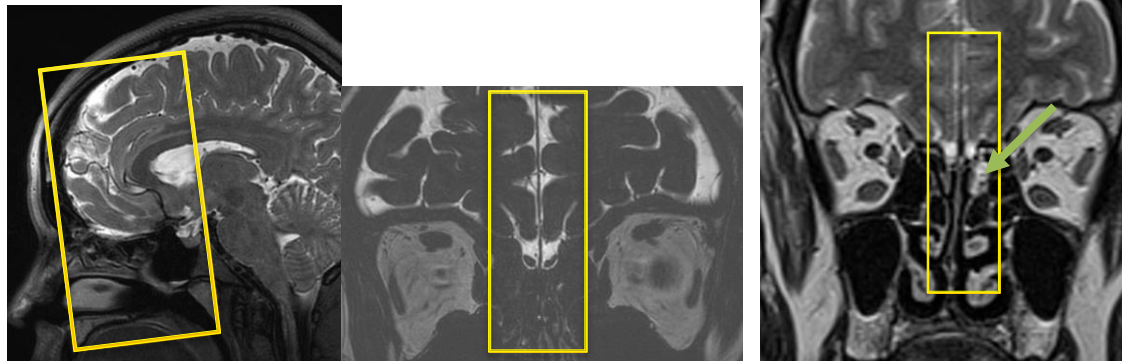


MR Cisternogram (CSF leak/ rhinorrhea/ otorrhea*) WO

SAG T2 TSE	3mm	22cm	Midline only
COR T2	2mm		From frontal sinus to post sella
Cor FIESTA /CISS/T2SPACE	0.6	18	Centered at the region of leak if visible on cor T2
Sag FIESTA /CISS/ T2SPACE	0.6		Centered at the region of leak if visible on cor T2
AX T2	3mm	18-21	Mouth opening to top of frontal sinuses
AX T1	3mm	18-21	Mouth opening to top of frontal sinuses
3D FLAIR-CUBE			Brain

*for all CSF leak try to ask radiologist for placement of slabs, especially for FIESTA planning

* for otorrhea (CSF leak from ear); the coronals have to be placed centered at the temporal bone and dedicated sagittal (R or L) off-midline, centered at the temporal bone as well.



Cor T2 plan

Sag T2 plan

Cor FIESTA plan